

Multispectral Optical Imaging of Skin-Lesions for Detection of Malignant Melanomas

Atam P. Dhawan, Brian D'Alessandro, Sachin Patwardhan and Nizar Mullani

Department of Electrical & Computer Engineering, New Jersey Institute of Technology, Newark, NJ USA
Translite Inc., Sugarland, TX, USA

Abstract—Optical imaging of skin-lesions for early detection and management of the most fatal skin-cancer malignant melanoma is of significant interest in mass screening of skin-lesions with high-risk population. Surface illumination based optical imaging methods such as epiluminescence light microscopy (ELM) through “Dermascopy” has shown a significant potential in improving early diagnosis of malignant melanomas. Limitations of surface reflectance based imaging systems have been realized in analyzing images for important vascular and depth dependent information. We have developed a novel optical imaging system, the Nevoscope, that uses multispectral transillumination as to provide images of skin-lesions showing sub-surface pigmentation as well as vascular architecture based blood volume information. This paper presents multispectral Nevoscope transillumination method to compare and analyze ratiometric measurements to epiluminescence imaging for its ability to discriminate malignant melanomas from dysplastic nevi and other normal skin-lesions.

I. INTRODUCTION

Skin cancer is the most common malignancy of mankind representing about one-half of all new detected cancers.

Skin cancers currently account for more than two-thirds of all new cancers in the U.S -- with more than 1,000,000 cases diagnosed each year. Melanoma --the most deadly of the skin cancers with incident rate rising worldwide faster than any other cancer -- is expected to cause almost 10,000 deaths in US this year. In its most advanced form, melanoma is as lethal as brain, lung and pancreatic cancers, with 80 percent of patients dying within five years. Early diagnosis is crucial in curing and preventing complications and death. [1].

It is clear that patients can benefit greatly if their skin cancers are diagnosed during the earliest stages of tumorigenesis. However, despite this knowledge the early diagnosis of skin cancer has remained a challenge for clinicians and researchers alike. In an effort to increase the diagnostic accuracy and sensitivity for detecting early skin cancers many researchers have begun to evaluate non-invasive optical imaging instruments such as the Dermascopy or the DermLite [1].

The current method of examining a skin lesion is to use surface lighting and some form of magnification lens. Most

of the information obtained about a nevus from surface lighting is from the reflected light from the skin/air boundary and the deeper pigmentation structure is often overcome by the surface reflection of the light. The diagnostic accuracy of visually detecting early melanoma by expert physicians is 58% and is lower for non-experts who do not specialize in early melanoma detection [1]. This accuracy is improved for advanced melanomas, which exhibit large changes in pigmentation and color in the skin lesion. A better accuracy for detecting melanoma can be obtained through the use of the Epiluminescence Light Microscopy (ELM) imaging method, where the reflection of the surface light is reduced by either an oil-glass interface on the skin (Dermoscope or cross-polarization of the surface and reflected light to cancel the surface reflection (MoleMax, DermLite, Oil-immersion epiluminescence microscopy (OELM)). It has been used by Wolf et al [1] to improve the accuracy of detecting early melanomas. Of course, the sensitivity for detecting melanoma varies with respect to the stage of the melanoma.

The ELM method of imaging skin-lesions utilizes surface reflectance dominant illumination techniques to allow the visualization of subsurface structures and colors. These subsurface structures and colors in combination with their location and distribution (pattern) have been shown to improve a clinician’s ability to detect early melanoma and basal cell carcinoma.

The ELM imaging can be performed utilizing polarized or non-polarized light. Cross-Polarization method for ELM imaging uses linear polarizer in the incident light and a viewing lens to cancel the light that is reflected from the skin. Since most of the reflected light from the skin surface has for the most part the same polarization angle as the incident light, cross-polarization blocks most of the surface reflected light and only the light that is diffused below the skin surface is visualized. Several investigators have demonstrated that the cross-polarization method of imaging with the ABCD rule can provide a comparable diagnostic accuracy for the detection of melanoma. Although, different illumination techniques allow for the visualization of many common structures and colors they are not identical. The non-contact cross-polarized dermoscopy method may prevent compression of blood vessels thus allowing for better visualization of the vascular plexus.

Though this primary imaging method provided a tool for better clinical management improving melanoma detection using comparative evaluation of images, the imaging methods is restricted to surface illumination that is unable to provide information about subcutaneous pigmentation and increased blood flow (angiogenesis), critical factors of early detection of malignant melanoma. Angiogenesis is an important facet of tumorigenesis. One method to characterize this process in pigmented lesions is to assess architectural patterns of vascular structures with tools that allow spectrometric measurement and analysis of deoxyhemoglobin

In this paper, we present a transillumination light microscopy (TLM) method of imaging skin-lesions as an additional mode of optical imaging techniques to capture the blood volume information from subsurface superficial and deeper vascular structures of skin-lesions. In this paper, we selected a non-contact polarized ELM method for comparison with TLM imaging method since the use of glass plate puts pressure on the skin surface causing a distortion in the superficial vascular architecture and change in blood flow in the respective sub-volume of the lesion. We compare polarized ELM with TLM imaging methods to demonstrate that TLM imaging method provides better vascular information from the subsurface lesion architecture. The increase in the blood volume as obtained from the ratio of the segmented pigment distribution areas between a TLM image and an ELM image of a skin lesion, shows promising correlation with the lesion progression.

II. METHOD

A. Nevoscope

Schematics of surface illumination and transillumination techniques used in, respectively, ELM and TLM imaging methods using the Nevoscope are shown in Figure 1a. For TLM imaging of skin-lesions, the Nevoscope uses a ring-light source based transillumination to transmit light directly into the skin area surrounding the lesion at an angle so that the light is focused underneath the surface of the skin behind the lesion. A virtual light source is thus created a few millimeters below the skin surface for uniform transillumination of a small area of the skin containing the skin-lesion. The skin lesion is positioned inside the transillumination ring through the opening providing a direct field of view to the digital camera through a zoom-lens assembly. In TLM imaging method, the light from the illuminator ring that is not reflected back due to a mismatch in refractive indices, enters into the skin and goes through multiple internal reflections and scattering. This light eventually gets diffused across the layers of the skin and back-scattered diffused light photons emerge from the skin to form a *transilluminated* image of the skin and skin-lesion.

Nevoscope design incorporates a ring-light source interface for transillumination, and an additional cross-polarized surface light source to providing all modes of ELM imaging including oil-based contact imaging by

adding a glass faceplate in the front of the lesion housing space. A no-glass faceplate model can be used for non-contact cross-polarization or transillumination modes of imaging. A schematic diagram of the Nevoscope is shown in Figure 1(b). Two independent optical fiber based channels provide light from the halogen light sources to the annular ring source for transillumination and ELM imaging via the four openings around the walls of the cylinder for surface illumination. Transillumination is achieved by the ring-light source only, which is in contact with the skin through the frontal interface to the skin. For cross-polarized ELM imaging, the polarized surface light is provided using another polarizing lens (cross-polarized by 90 degrees) and the ring-light source is turned off. The surface light intensity is adjusted by rotating a knob located on the light box. An optical magnification lens, with the ability of limited focal distance adjustment, is used for a 5 X magnification of lesions.

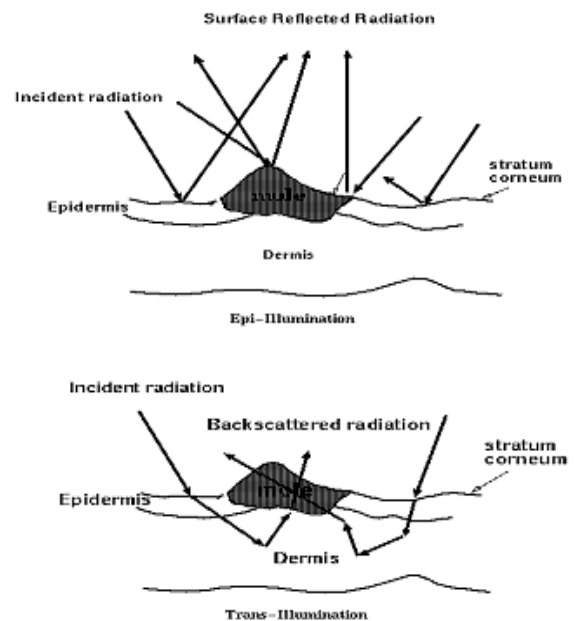


Figure 1(a). Schematic representation of surface-reflectance based epiluminescence imaging (top) and transillumination imaging (bottom) methods.

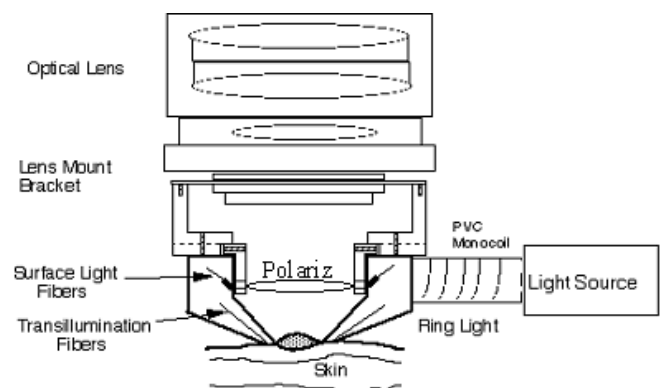


Figure 1. (b) A schematic diagram of the Nevoscope instrumentation.

B. Experimental Imaging Protocol

Patient were selected randomly from the clinical visits at the M.D. Anderson Cancer Center from the recommendations of attending dermatologists without regards to race or gender, but based purely on the appropriateness of pigmented lesions.. Each lesion was imaged using both ELM and TLM imaging methods using a Nevoscope designed through modifications on a Dermlite-II instrument to include TLM imaging methods [2]. After imaging, lesions were excised on voluntary basis or clinical reasons. The histopathology was performed at the M.D. Anderson Cancer Center for lesion classification and vascular blood volume measurements.

The pathology slides from the excised lesions were analyzed by an expert dermatopathologist at the University of Texas M D Anderson Cancer Center. The diagnosis was made blinded to the patient history or imaging results. The lesions were classified according to the list in Table 1. For this study, due to the low number of melanomas expected, dysplastic nevi were grouped with malignant melanomas for the computation of diagnostic accuracy.

Multispectral Nevoscope Images of Skin-Lesions

Multispectral Nevoscope images of skin-lesions were obtained with the following illumination and wavelength protocol:

1. White light surface illumination (ELM)
2. White-light transillumination (TLM)
3. 510 nm cross-polarized transillumination
4. 560 nm cross-polarized transillumination
5. 610 nm cross-polarized transillumination

While white-light cross polarized (TLM) images show the overall blood volume information, 510 nm image shows the superficial pigmentation, 560 nm image shows superficial vascularity and mid-depth pigmentation, and 610 nm shows the deep pigmentation (Figure 2).

C. Segmentation of Blood Volume Regions

In this study, each image, whether ELM or TLM, undergoes a completely automated procedure consisting of three main steps of processing, before the lesion in the image can be identified, namely preprocessing, segmentation, and data analysis. In turn, each main step consist of several sub-steps. The entire procedure is described below:

Preprocessing

- a. Quality control of the captured images to discard over exposed images or those with an air gap between the Nevoscope ring and the skin surface. The latter creates a shift in the captured image color space
- b. Resize: Original images have a very high resolution of 1368 x 1712 pixels and an approximate size of 1.5 MB. To reduce the size of an image, and thus increase the processing

speed, images are resized to 256 x 320 pixels using bicubic interpolation. These values maintain the original aspect ratio of the image.

- c. Masking: Furthermore, images have a circular bright ring all around the lesion, due to reflection of light from the edge of the glass plate. To remove this bright ring of light, a binary mask with a circular diameter 256 pixels is generated, and centered at the center of the lesion, which is defined as the intersection of the two diagonals of the image. Then, the mask is multiplied with the image to produce a new image.

- d. Cropping: Finally, the Image is cropped to a 256 x 256 image to remove the extra black background around the disc.

- e. Hair Removal: The artifact can be removed, or its effect minimized, by median filtering the image with a structuring element of size of [1 x 4] and [4 x 1].

Image Segmentation

- a. Image normalization to control the dynamic range of the color space followed by histogram equalization for contrast improvement.

- b. $L^*a^*b^*$ color space transformation for better separation of the pigment information from the illumination and light intensity artifacts.

- c. The two types of images to be segmented: ELM and TLM contain information about the melanin and hemoglobin distributions respectively. Melanin information from the ELM images was highlighted by a combined color space obtained using: $(a^* + b^*) - L^*$. Hemoglobin information from the TLM images was highlighted by a combined color space obtained using: $(L^*) \times (a^*)$.

- d. Adaptive threshold was calculated for the combined color space images using Otsu's method [3]. This thresholding technique chooses the threshold to minimize the intra-class variance of the black and white pixels.

- e. Thresholds were used to convert the images in to binary images and the pigmented area was then segmented using standard morphological operations.

Data Analysis

- a. After segmentation of the ELM and TLM images the surface area of the segmented regions were calculated.

- b. The ratio of the melanin and hemoglobin pigment distribution area was correlated with the lesion type information obtained from pathological evaluation. Images using ELM and TLM imaging methods for forty lesions were segmented and the area of the segmented lesion was computed. Each image was verified independently by a dermatoptahologist for its segmented regions.

III. RESULTS

A total of 280 lesions comprising of benign, compound, dysplastic nevi and 24 malignant melanomas were used in this study. The average ratios for benign and compound nevi were observed respectively as 1.028 and 1.091 where the

ratios for mild and moderate dysplastic nevi were determined 1.127 and 1.214 respectively. The average ratio for malignant melanoma was observed to be much higher at 1.854 showing a much larger blood volume for malignant lesions.

Lesion Type	Average TLM/ELM Ratio	Stand. Devi. TLM/ELM Ratio
Benign Nevi (n=68)	1.028	0.1333
Compound Nevi (n=53)	1.091	0.0468
Dysplastic Nevi-Mild (n= 78)	1.127	0.0444
Dysplastic Nevi-Moderate (n=57)	1.214	0.0452
Malignant Melanoma (n=24)	1.854	0.0168

Table 1: Average and standard deviation of the TLM/ELM ratio for different lesion types.

IV. CONCLUSION

In this paper, a Nevoscope transillumination method to acquire vascular architecture information has been discussed and analyzed to compare with the lesion information provided by the epiluminescence imaging method for its ability to measure vascular information for characterization of skin-lesions. The analysis on the ratio of segmented regions from transillumination and epiluminescence has shown to be correlated with the pathology of the skin-lesion. It has been shown that the malignant lesions has higher ratio of the segmented regions computed from transillumination

image to epiluminescence image of the same lesion due to increased blood flow. The benign lesions with normal blood flow provided the approximately the same segmented region computed from the transillumination and epiluminescence images. Blood volume area segmentation results from 510 nm and 560 nm images were found to be similar without any statistically significant difference while 610 nm image provided deep pigmentation information. Thus, multispectral transillumination images provide important information about vascular structure and blood flow around the lesion. Further work is being conducted with higher near-infrared (NIR) wavelengths based multispectral transillumination imaging to more accurately determine the vascular hemoglobin and de-oxy-hemoglobin information.

ACKNOWLEDGMENT

We acknowledge the kind support from the George A. Ohl Jr. Trust Foundation, and the Gustavus and Louise Pfeiffer Research Foundation. We also thank Dr. Madeleine Duvic for clinical imaging.

REFERENCES

- [1] Wolff K, Binder M, Pehamberger H: Epiluminescence microscopy: a new approach to the early detection of melanoma. *Adv in Derm.* 1994;9:45-56
- [2] Dhawan A. P., "Apparatus and Method for Skin Lesion Examination", US Patent Number 5,146,923, 1992.
- [3] Otsu, N., "A Threshold Selection Method from Gray-Level Histograms," *IEEE Transactions on Systems, Man, and Cybernetics*, Vol. 9, No. 1, 1979, pp. 62-66.

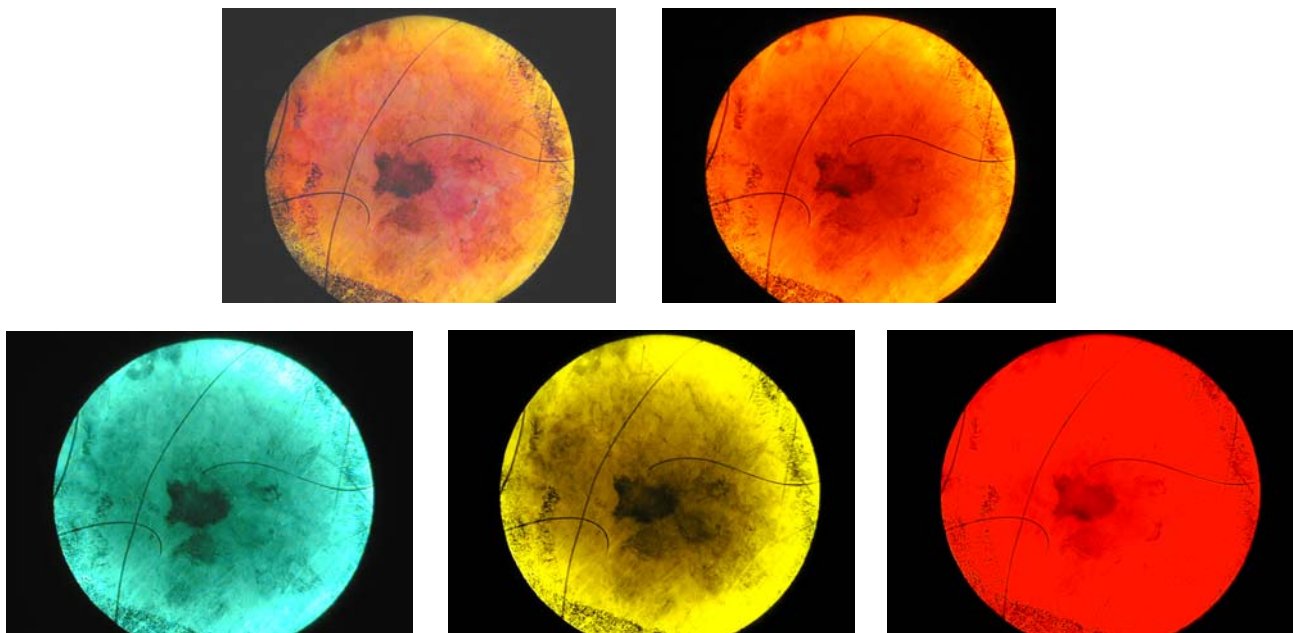


Figure 2: Multispectral Nevoscope images (From top left to bottom right: White light ELM, White light TLM, 510 nm TLM, 560 nm TLM and 610 nm TLM).